

# Principles of Breast Re-Reduction: A Reappraisal

Raakhi M. Mistry, M.B.Ch.B.  
Susan E. MacLennan, M.D.  
Elizabeth J. Hall-Findlay,  
M.D.

Christchurch, New Zealand; and Banff,  
Alberta, Canada



**Background:** This article examines outcomes following breast re-reduction surgery using a random pattern blood supply to the nipple and vertical scar reduction.

**Methods:** A retrospective review was conducted of patients who underwent bilateral breast re-reduction surgery performed by a single surgeon over a 12-year period. Patient demographics, surgical technique, and outcomes were analyzed.

**Results:** Ninety patients underwent breast re-reduction surgery. The average interval between primary and secondary surgery was 14 years (range, 0 to 42 years). The majority of patients had previously undergone primary breast reduction using an inferior pedicle [ $n = 37$  (41 percent)]. Breast re-reduction surgery was most commonly performed using a random pattern blood supply, rather than recreating the primary pedicle [ $n = 77$  (86 percent)]. The nipple-areola complex was repositioned in 60 percent of patients ( $n = 54$ ). The mean volume of tissue resected was 250 g (range, 22 to 758 g) from the right breast and 244 g (range, 15 to 705 g) from the left breast. Liposuction was also used adjunctively in all cases (average, 455 cc; range, 50 to 1750 cc). Two patients experienced unilateral minor partial necrosis of the areolar edge but not of the nipple itself (2 percent).

**Conclusions:** Breast re-reduction can be performed safely and predictably, even when the previous technique is not known. Four key principles were developed: (1) the nipple-areola complex can be elevated by deepithelialization rather than recreating or developing a new pedicle; (2) breast tissue is removed where it is in excess, usually inferiorly and laterally; (3) the resection is complemented with liposuction to elevate the bottomed-out inframammary fold; and (4) skin should not be excised horizontally below the inframammary fold. (*Plast. Reconstr. Surg.* 139: 1313, 2017.)

**CLINICAL QUESTION/LEVEL OF EVIDENCE:** Therapeutic, IV.

**B**reast reduction is a common surgical procedure. Although numerous studies have demonstrated high levels of patient satisfaction following surgery, a proportion of these patients present again for breast re-reduction. Indications include inadequate volume reduction, poor shape, asymmetry, and recurrent glandular hypertrophy.<sup>1,2</sup> To date, there is no consensus on the safest and most effective surgical technique for breast re-reduction surgery.<sup>3</sup>

A number of different dermoparenchymal pedicles have been successfully used for breast reduction surgery, including inferior, superior, superomedial, and lateral pedicles.<sup>4</sup> Maintenance of blood supply to the nipple-areola complex is an important surgical consideration when planning

breast re-reduction surgery. Theoretically, if an inferior pedicle was used at primary surgery, the dominant blood supply at re-reduction surgery is still from the inferior pedicle. The blood supply to a superior or superomedial pedicle would have been transected at primary surgery, and although neovascularization occurs in the surrounding tissue,<sup>5</sup> it may not be enough to support the nipple-areola complex if a different pedicle is used at re-reduction surgery. The question of whether to recreate the primary pedicle versus relying on random pattern blood supply has been debated in the literature, yet there is no definite consensus.<sup>6-11</sup>

Another complicating factor is that the primary pedicle is often not known. In many cases, the original surgeon is not the surgeon performing the re-reduction surgery. This has been our

From Christchurch Hospital and Banff Plastic Surgery.  
Received for publication September 2, 2016; accepted  
December 12, 2016.  
Copyright © 2017 by the American Society of Plastic Surgeons  
DOI: 10.1097/PRS.0000000000003383

**Disclosure:** The authors have no financial disclosures to report.

experience and is corroborated by a number of studies.<sup>6–11</sup> This adds further complexity to the decision-making process for the breast re-reduction surgeon.

Necrosis of the nipple-areola complex is a recognized complication of breast re-reduction surgery. The risk may depend on which pedicle is used, how far the nipple-areola complex is repositioned, and the volume of breast tissue resected.<sup>1–4,6–11</sup> A handful of studies have reported outcomes following breast re-reduction surgery, but each is limited by retrospective design, small sample size, and variable outcome measures reported.

Although Lejour reported few complications,<sup>6</sup> Hudson and Skoll<sup>7</sup> reported nipple-areola necrosis in one patient when the original pedicle was recreated and in one patient where a new pedicle was created (of 16 patients). Losee et al.<sup>8–10</sup> reported on 10 patients with no complications with either a new pedicle or a recreated original pedicle. Patel et al.<sup>11</sup> reported on eight patients, with one developing necrosis with recreation of the original pedicle. Ahmad et al.<sup>1,2</sup> reported 23 patients with no necrosis (Table 1).

This retrospective review was undertaken because experience with these patients allowed the senior author (E.H.F.) to determine strategies and principles to overcome problems and avoid complications encountered in breast re-reduction:

1. A reliable way to correct glandular ptosis is to remove a vertically oriented inferior wedge of skin and breast tissue. This often entails removal of a previous inferior pedicle, which could put the blood supply to the nipple at risk.
2. Developing a new pedicle does not make sense from a blood supply standpoint because blood vessels supplying a new pedicle would have been transected during creation of the original pedicle. The senior

author believes that as long as a random pattern blood supply to the nipple can be maintained, the risk of nipple-areola complex necrosis should be minimized, thereby allowing removal of the original pedicle.

3. Unweighting the breast by removing parenchyma inferiorly and performing liposuction between the bottomed-out inframammary fold and the inframammary fold scar allows the fold to rise.
4. To allow the bottomed-out inframammary fold to rise, skin should not be removed horizontally below the inframammary fold scar. That skin originally belonged to the chest wall, and removing it would likely pull down the inframammary fold. The skin should be retained so that it can revert back to the chest wall. If there is significant skin redundancy, it should be removed above the inframammary fold scar so that the fold can rise.

## PATIENTS AND METHODS

A retrospective review was performed of all patients who underwent bilateral breast re-reduction surgery between June of 1993 and June of 2015. There were 90 patients in total. Indications for re-reduction included inadequate volume reduction, poor shape, asymmetry, and recurrent mammary hypertrophy. Revision procedures such as scar revisions and excision of dog-ears were excluded. Baseline demographics, surgical technique, and outcomes were obtained from medical records. All breast re-reduction cases were performed by a single surgeon (E.H.F.). The minimum postoperative follow-up was 6 months (Table 2).

When the nipple-areola complex did not need to be moved (18 patients), an inferior wedge of skin and breast tissue was removed through a vertical incision. Excess parenchyma

**Table 1. Review of Breast Re-Reduction Literature**

Reference	No. of Patients	Pedicle	No. of Patients	NAC Necrosis
Lejour, 1997 <sup>6</sup>	14	Original pedicle recreated	9	0
Hudson and Skoll, 1999 <sup>7</sup>	16	Original pedicle recreated	5	1
		New pedicle created	3	1
Losee et al., 2000 <sup>8</sup>	10	Original pedicle recreated	3	0
		New pedicle created*	7	0
Patel et al., 2010 <sup>11</sup>	8	Original pedicle recreated	4	1
		New pedicle created	3	0
Ahmed et al., 2012 <sup>1</sup>	23	De-epithelialized (“superior”)	23	0

NAC, nipple-areola complex.

\*Several of these patients actually had part of the original vertical bipedicle included.

**Table 2. Patient Characteristics and Surgical Data**

Characteristic	Value (range)
Primary BBR	
BBR by another surgeon	71
BBR by author	19
Age, yr	
Average	30
Range	13–56
Pedicle	
Superomedial	8
Superior	8
Inferior	37
Lateral	6
Medial	8
Mastopexy	4
Central	1
Bipedicle horizontal	1
Unknown	17
Skin pattern	
Inverted T	59
Vertical	30
Dufourmental	1
Re-reduction	90
Age, yr	
Average	45
Range	15–73
Technique/pedicle	
Primary pedicle recreated	13
Vertical wedge only	18
Vertical wedge plus de-epithelialization for NAC reposition	59
Skin pattern	
Inverted T	3
Vertical	71
Vertical with J/L extension	16
NAC repositioned, no.	54
Average NAC reposition, cm	2.3 (0.5–6)
Rep-reduction mass	
Right, g	250 (22–758)
Left, g	244 (15–705)
Liposuction, both breasts, cc	455 (50–1750)
Complications	
Partial NAC necrosis	2
Hematoma	1

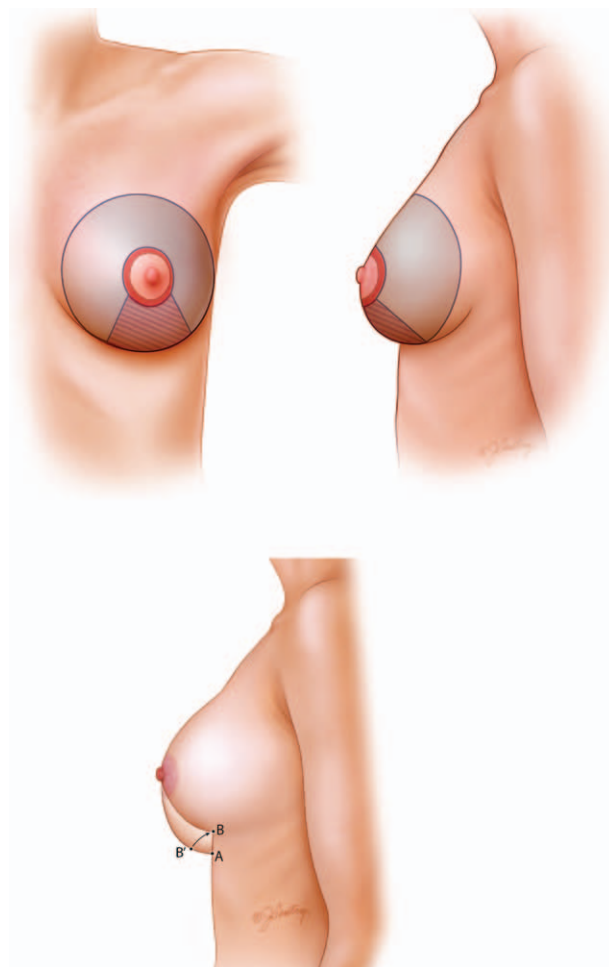
BBR, bilateral breast reduction; NAC, nipple-areola complex.

beyond and inferior to the Wise pattern (Fig. 1, *above*) was removed by direct excision and/or liposuction.

In some of the earlier cases, an attempt was made to recreate the original pedicle (13 patients). Figure 4 shows a patient for whom the inferior pedicle was recreated.

In the later cases (59 patients), as the principles were developed, the technique was modified as follows:

1. Standard<sup>12</sup> vertical skin-marking pattern with de-epithelialization of the area around the nipple-areola complex was used. No new pedicle was created. A random pattern blood supply was maintained by de-epithelialization only, with minimal undermining deep to the nipple-areola complex.



**Fig. 1.** (*Above*) Breast re-reduction with removal of a vertically oriented inferior wedge of skin and parenchyma (*cross-hatched area*). The skin around the areola is de-epithelialized only, and no new pedicle is created. The rest of the parenchyma is left behind in the Wise pattern so that it is coned into a good shape with closure of the pillars. (*Below*) A-B is bottomed-out breast skin that should not be excised. It needs to revert to chest wall skin. This is achieved by removal of weight, both with excision of the inferior wedge and with liposuction. (Printed with permission from ©JGentry.)

2. A vertically oriented inferior wedge excision en bloc of skin, fat, and gland was used to remove the excess glandular ptosis.
3. Liposuction was performed in both the breast and between the inframammary fold and the horizontal scar. Either direct or tumescent infiltration was used, depending on the anticipated liposuction volume.
4. Excess parenchyma and fat between the bottomed-out inframammary fold and the original inframammary scar was removed to elevate the inframammary fold without the need for sutures to the chest wall.

## RESULTS

Ninety patients underwent bilateral breast re-reduction surgery between June of 1993 and June of 2015 (Table 2).

### Primary Breast Reduction

Patients underwent their primary breast reduction surgery between 1968 and 2013. Primary breast reduction surgery was performed by a variety of surgeons, including the senior author (E.H.F.) [ $n = 19$  (21 percent)]. The average age of patients at primary breast reduction was 30 years (range, 13 to 56 years). The most common pedicle used at primary surgery was inferior [ $n = 37$  (41 percent)], followed by superomedial ( $n = 8$ ), superior ( $n = 8$ ), medial ( $n = 8$ ), and lateral ( $n = 6$ ). The original pedicle was not known in 17 patients. The majority of patients had inverted-T scars [ $n = 59$  (66 percent)].

### Breast Re-Reduction

The average interval between primary breast reduction and breast re-reduction surgery was 14 years (range, 0 to 42 years). The average age at breast re-reduction was 45 years (range, 15 to 73 years).

The majority of re-reductions used a vertical scar pattern [ $n = 71$  (79 percent)], followed by a vertical scar with a J or L extension [ $n = 16$  (18 percent)]. An inverted-T scar was repeated in two cases when skin resection was required [ $n = 3$  (3 percent)]. Re-reduction was most commonly performed using a random pattern blood supply by de-epithelialization only, rather than recreating the primary pedicle [ $n = 77$  (86 percent)]. The nipple-areola complex was repositioned in 60 percent of patients ( $n = 54$ ). The average nipple-areola complex elevation was 2.3 cm (range, 0.5 to 6 cm). The mean volume of tissue resected was 250 g (range, 22 to 758 g) from the right breast

and 244 g (range, 15 to 705 g) from the left breast. Standard liposuction was used in all cases [average, 455 cc total per patient (not separated per breast); range, 50 to 1750 cc).

Seven patients (only counted once) underwent more than one breast re-reduction procedure (8 percent). One patient underwent three breast reduction procedures because her initial breast reduction (body mass index of 26 kg/m<sup>2</sup>) was performed at age 13 years (929 g/711 g plus 400 cc standard liposuction), then again at age 15 (758 g/494 g plus 250 cc), and again when she was almost 18 (163 g/209 g plus 200 cc). In the group of patients who had more than one breast re-reduction, the mean volume of tissue resected from the right breast was 123 g (range, 59 to 186 g), and the mean volume resected from the left breast was 166 g (60 to 355 g). Adjunctive liposuction was used in all cases (average, 218 cc; range, 50 to 408 cc). Breast re-reductions were performed in patients who still felt too large, in patients who wanted some shape correction, and in patients with recurrent hypertrophy.

One patient experienced a postoperative hematoma requiring evacuation (1 percent). Two patients experienced minor partial necrosis of the areola edge but not of the nipple itself (2 percent). These cases are listed in Table 3. The first patient probably shows that the de-epithelialization was carried beyond the limit of safety of a random pattern blood supply because the nipple was elevated 6 cm. The second patient mistakenly had a medial pedicle created at the re-reduction when the original pedicle was laterally based. Both cases were managed conservatively and healed uneventfully.

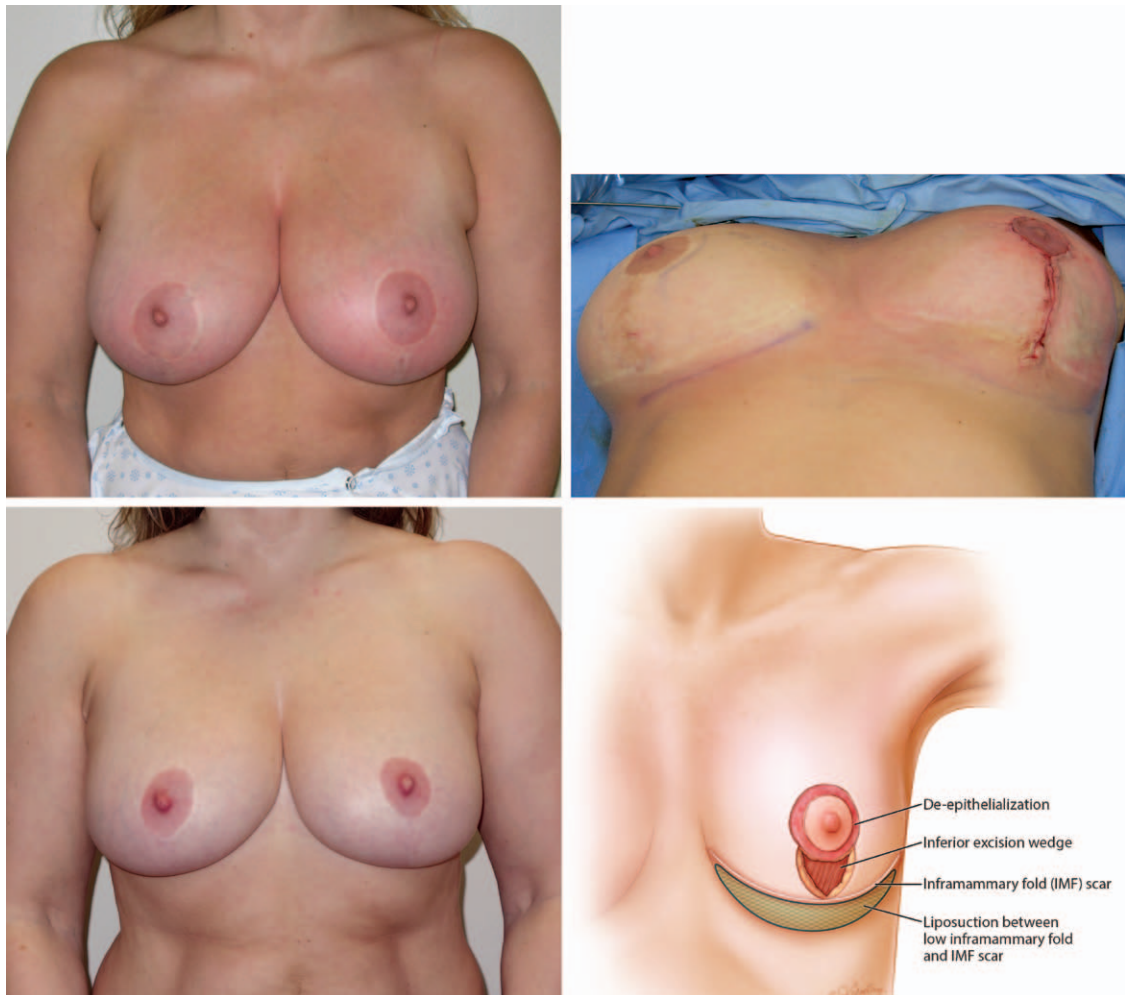
## DISCUSSION

Women presenting for breast re-reduction surgery can pose a surgical challenge. Problems requiring correction include glandular

**Table 3. Patients with Partial Nipple-Areola Complex Necrosis**

	Patients with Partial NAC Necrosis	
	Patient A	Patient B
Original pedicle	Strombeck horizontal bipedicle	Lateral
Original skin pattern	Inverted T	Vertical
Re-reduction "pedicle"	Random pattern de-epithelialization	Creation of medial pedicle
Re-reduction skin pattern	Vertical	Vertical plus J/L extension
Smoking status	Nonsmoker	1 pack/day
NAC elevation, cm	6	2
Left breast re-reduction, g	225	425
Right breast re-reduction, g	175	425
Liposuction, cc	100	100
Management	Wound care	Wound care

NAC, nipple-areola complex.

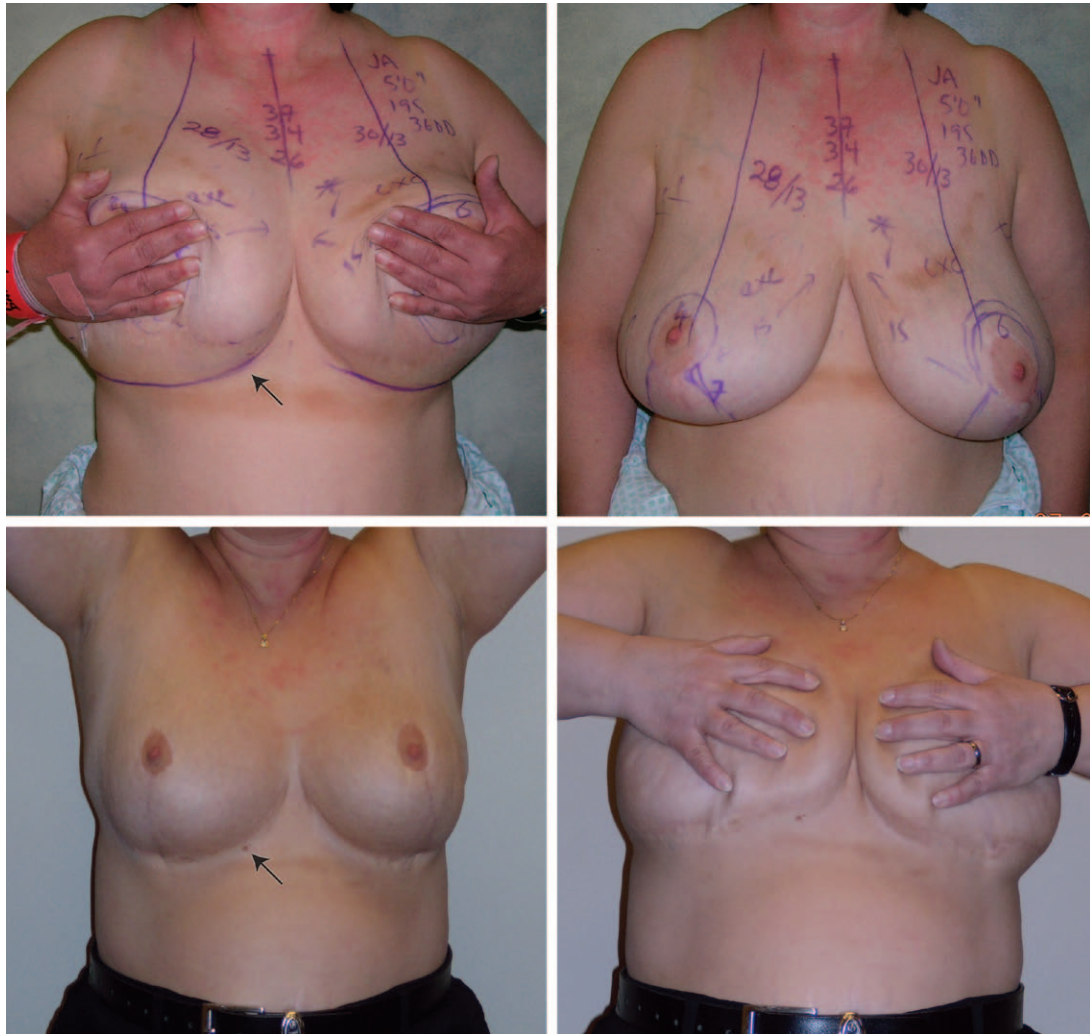


**Fig. 2.** (Above, left) This 39-year-old woman had a previous breast reduction with an unknown pedicle. Re-reduction involved removal of a vertically oriented inferior wedge of skin and breast tissue along with liposuction. One hundred eighty grams was excised from the right breast and 160 g was excised from the left breast; 350 cc of fat using liposuction was removed from the breasts and above the inframammary fold on both sides. (Above, right) The markings on the right breast in the intraoperative photograph show that minimal de-epithelialization was to be performed around the areola. A new pedicle is not created. The areola relies on a random pattern blood supply. The vertical wedge resection removes the glandular ptosis and helps control the horizontal base diameter of the breast and improves projection. The horizontal scar is not revised, nor is the inframammary fold sutured to the chest wall. (Above previously published in Hall-Findlay EJ. *Aesthetic Breast Surgery: Concepts and Techniques*. St. Louis: Quality Medical; 2011:418. Images used with permission.) (Below, left) Six years after the re-reduction with good improvement of the glandular ptosis. The lower pole of the breast was almost at the level of the elbow crease preoperatively. The elevation was maintained postoperatively. (Below, right) The illustration shows that the principles of re-reduction include removal of the glandular ptosis, random pattern–only blood supply to the nipple, no horizontal skin excision, and liposuction (green hatched area) to unweight the breast and elevate the fold. (Printed with permission ©JGentry.)

hypertrophy, high nipple position, descent of the inframammary fold, and glandular ptosis. The goal of this study was to review the safety and efficacy of breast re-reduction surgery (1) using a vertically oriented inferior wedge reduction of skin and parenchyma, (2) maintaining a random pattern blood supply to the nipple-areola complex

by de-epithelialization only, and (3) elevating the inframammary fold by unweighting the breast.

Patients who presented with high nipple position were best managed with resection of the lower pole of the breast to try to adapt the mound to the nipple position. This was the preferred option because it is almost impossible to lower a nipple

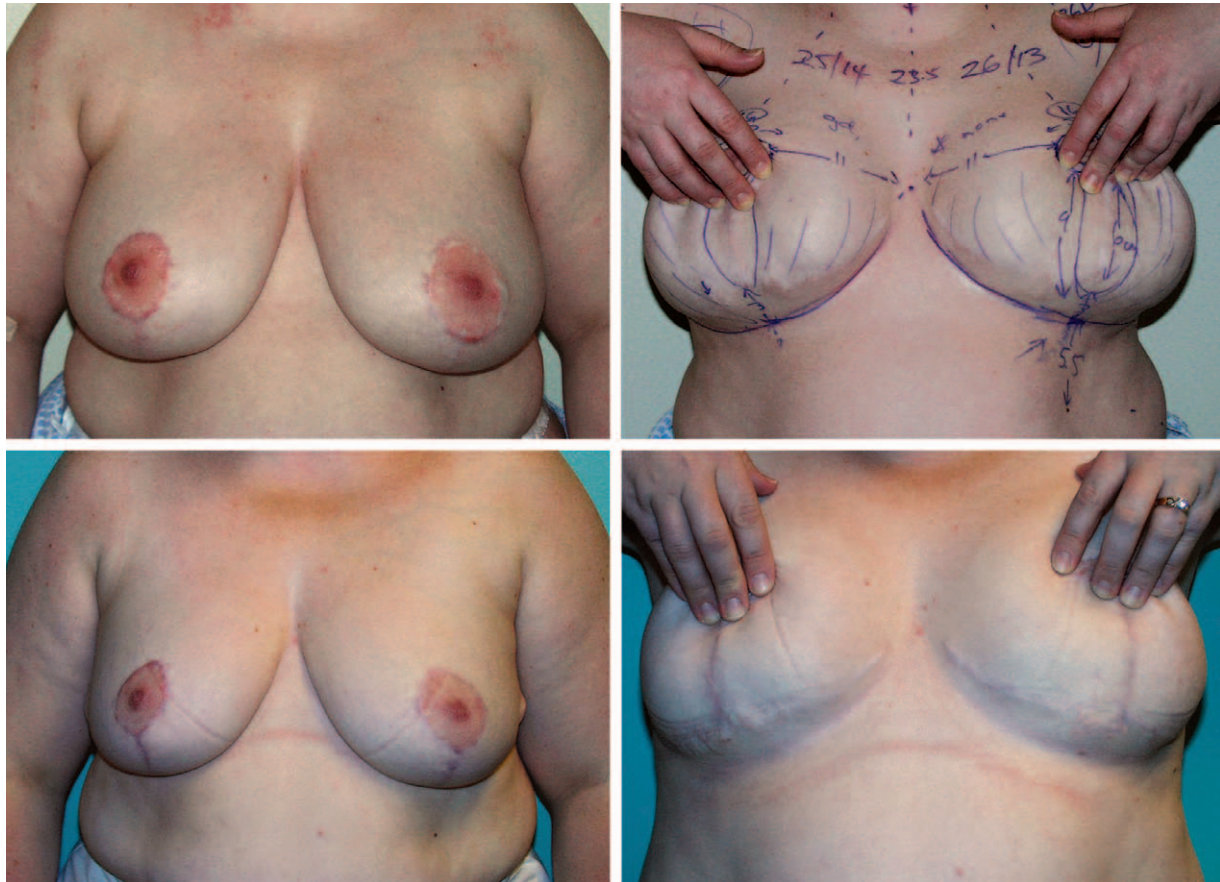


**Fig. 3.** (Above, left) This 45-year-old woman underwent a previous breast reduction in Europe with an unknown pedicle. A vertical wedge resection was used without violating the previous inframammary scar. The skin around the areola was de-epithelialized without creation of a pedicle. (Above, right) Note the bottomed-out inframammary fold well below the inframammary fold scar. Re-reduction involved excision of an inferior vertical wedge of skin and breast tissue with removal of 385 g from the right breast and 395 g from the left breast; 475 cc of fat was also removed from the breasts and from the area between the inframammary fold and the horizontal scar on both sides. (Below) Five years after the re-reduction, with good maintenance of the inframammary fold elevation. There was no revision or excision of skin along the inframammary fold scar. Elevation of the inframammary fold is achieved through removal of the inferior vertical wedge of parenchyma plus liposuction between the bottomed-out inframammary fold and the previous inframammary scar. There was no horizontal skin removal and no attempt to secure the inframammary fold to the chest wall. After liposuction, the skin that was originally caudal to the inframammary fold is converted back to chest wall skin. The arrow shows a mole in the previous inframammary scar for reference. (Above previously published in Hall-Findlay EJ. *Aesthetic Breast Surgery: Concepts and Techniques*. St. Louis: Quality Medical; 2011:416. Images used with permission.)

without leaving unsightly scars in the upper pole of the breast.

Breast re-reductions can often be performed safely when the nipples are in a relatively good position. The problem is usually glandular ptosis and bottoming-out of the inframammary

fold. When the nipple-areola complex does not need to be moved, an inferior wedge of skin and parenchyma can be safely removed because this is unlikely to affect the blood supply to the nipple-areola complex. The excess tissue is removed where it is in excess—inferiorly.



**Fig. 4.** (Above) An inferior pedicle was recreated in this patient, but this did not allow any elevation of the inframammary fold. The re-reduction was accomplished with the excision of 260 g from the right breast and 285 g from the left breast. A total of 950 cc of fat was removed using liposuction. (Below) The patient is shown at 7 months after her reduction, and it can be seen with the breasts lifted that there was no elevation of the inframammary fold. Recreation of the inferior pedicle did not allow weight to be removed from the lower pole of the breast, and the lower breast skin was not reverted to chest wall skin. (Previously published in Hall-Findlay EJ. *Aesthetic Breast Surgery: Concepts and Techniques*. St. Louis: Quality Medical; 2011:425–426. Images used with permission.)

A careful analysis of previous reports shows that even recreating the original pedicle in a breast re-reduction can result in significant complications.<sup>7,11</sup> In cases where the nipple needs to be elevated, recreating the original pedicle is not recommended.

There are several recent reviews of nipple-sparing mastectomy in patients who have previously undergone breast reduction or mastopexy.<sup>5,13,14</sup> The procedure is safe, provided that the nipple is not being moved, even when there is a previous circumareolar or infraareolar scar. Spear et al. discuss simply deepithelializing around the areola if it needs to be elevated, then removing an inferior wedge of breast skin and parenchyma either immediately or later when the nipple-sparing mastectomy is performed.<sup>13</sup> This principle can also be applied to re-reductions.

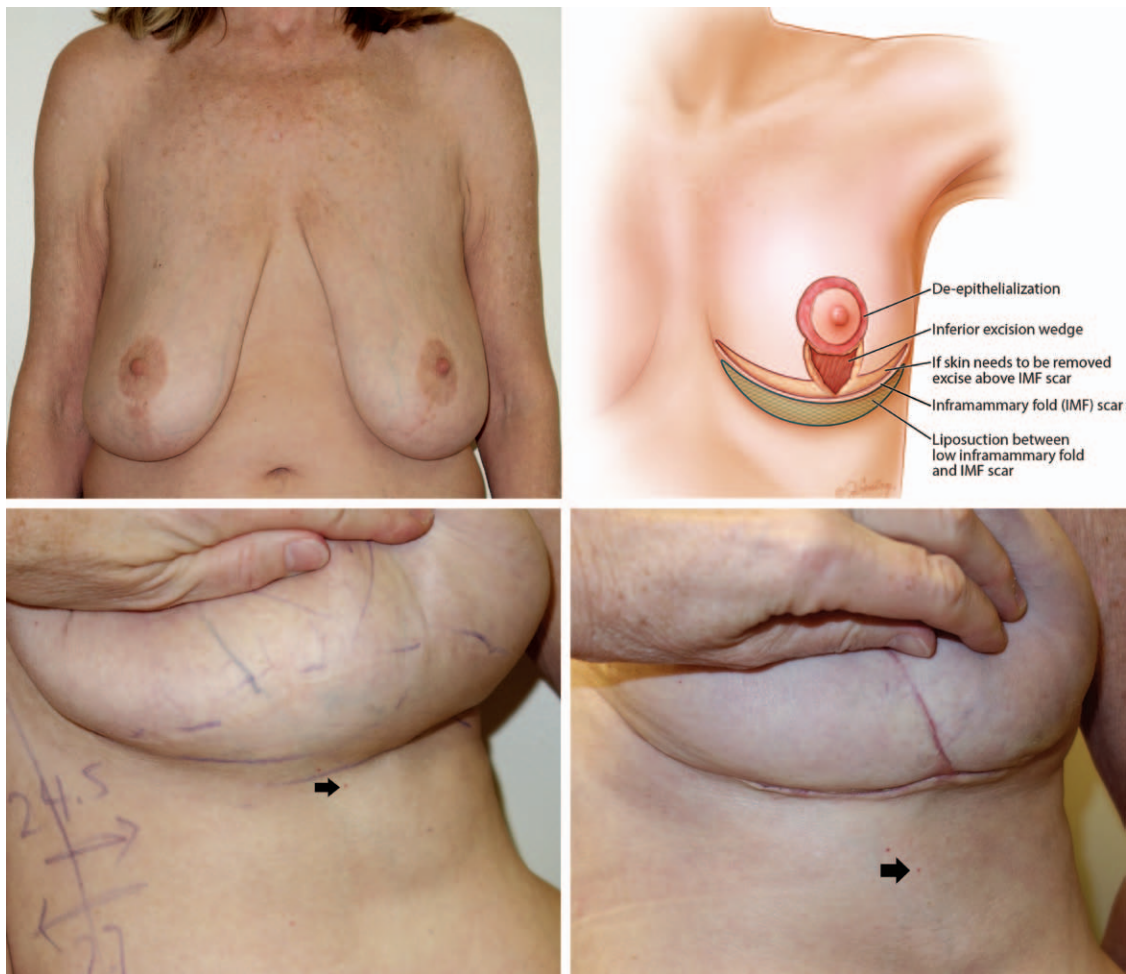
Ahmad et al. recommended carefully creating a superior pedicle when the previous pedicle is unknown, to maintain the blood supply.<sup>1,2</sup> In fact, what the authors recommend is deepithelializing enough to raise the nipple but maintaining the blood supply not on a new “pedicle” but on a random pattern blood supply that would have developed after the original procedure. We are in agreement with this approach.

A frequent problem with breast reduction, particularly inferior pedicle techniques, is descent of the inframammary fold below the original scar. Many surgeons approach a previous breast reduction patient who has a low inframammary fold (often several centimeters lower than the original inframammary fold scar) by trying to push the inframammary fold up into the scar by excising skin and tissue horizontally. This maneuver

is ineffective because that extra skin is needed (Fig. 1, *below*). The skin between the horizontal scar and the lower inframammary fold was originally chest wall skin. When the breast drops with time (more common when an inferior pedicle is used), the skin that was originally chest wall skin becomes breast skin and the original inframammary fold incision migrates up onto the lower pole of the breast.

The skin below the horizontal scar should be reverted to chest wall skin (Figs. 1 through 5). This can be accomplished by removing weight from

the inframammary fold area. No suturing is done to elevate the fold. The vertically oriented inferior wedge of skin and breast tissue is resected, which by itself results in elevation of the inframammary fold. Any parenchyma below the horizontal scar is removed, and this is complemented with liposuction. This unweights the breast and allows the inframammary fold to rise and preserves the parenchyma in the Wise pattern distribution (Fig. 1, *above*). Occasionally, some skin will need to be removed if it is in significant excess, but any skin resection horizontally should be performed *above*



**Fig 5.** (*Above*) In this re-reduction patient, a vertical wedge resection alone would not be adequate. She needed a Wise pattern skin resection on the breast and removal of significant redundant skin. It is important in these cases to leave the skin intact between the bottomed-out inframammary fold and the previous horizontal scar. That skin needs to be preserved so that it can revert to chest wall skin. The redundant skin should be removed from above the horizontal scar, not below. (Printed with permission ©JGentry.) (*Below, left*) The dotted line marks the previous inframammary scar. The inframammary fold itself has significantly bottomed-out and the skin between the scar and the fold should not be removed; otherwise, it will pull the inframammary fold down. The arrow marks a cherry angioma for reference to show how the inframammary fold was raised. (*Below, right*) The redundant skin was removed from above the inframammary scar, and the inframammary fold has been able to rise with removal of weight through direct excision of parenchyma complemented with liposuction. The inframammary fold was not sutured down to the chest wall.



the original inframammary fold incision rather than below (Fig. 5). This will ensure that when the skin below the horizontal scar is returned to its correct place on the chest wall, the inframammary fold scar is in the correct location.

When the primary reduction uses a superior, medial, or superomedial pedicle, it is less common to see significant bottoming-out of the inframammary fold, because lower breast tissue was resected with the original reduction. In these cases, inferior wedge resection and liposuction play the primary roles in re-reduction, without the need to address a bottomed-out inframammary fold. Occasionally, skin resection is deemed necessary during the re-reduction. In these cases, skin is resected above the inframammary fold (Fig. 5).

This review has allowed us to make recommendations for safe, predictable breast re-reduction surgery with a minimum of complications. The following principles have emerged:

1. It is important to understand the blood supply of the nipple and areola.<sup>15,16</sup> If the primary pedicle is removed, the blood supply will be random pattern. Re-reduction can be performed safely, provided that the surgeon respects that a random pattern blood supply will not allow the nipple to be significantly elevated. The longest elevation in this series was 6 cm, and although significant tissue connection deep to the nipple-areola complex was maintained in that case, this was one of the cases that developed partial nipple-areola necrosis. It is probably best to avoid elevating the nipple as much as 6 cm. It may be better in such cases to consider a free nipple graft.
2. Excess tissue is usually located in the inferior pole. Vertically oriented inferior wedge resection of the inferior pole is an effective way of removing this excess. This inferior wedge resection allows removal of the glandular ptosis and provides good control of the horizontal base diameter of the breast.
3. In most cases, skin should not be excised between the bottomed-out inframammary fold and the inverted-T scar because the skin below the horizontal scar needs to be converted back to its original location on the chest wall so that the bottomed-out inframammary fold can rise. In the rare case where skin resection is necessary, skin should be excised above the original inframammary fold scar.
4. Liposuction is an important adjunct to remove excess tissue inferiorly between the inframammary fold and a previous horizontal



## CODING PERSPECTIVE

Coding perspective provided by Dr. Raymond Janevicius is intended to provide coding guidance.

### 19318 Reduction mammoplasty

- All breast reduction procedures are reported with code 19318. There is no separate code for secondary reduction or re-reduction.
- Although the re-reduction procedure may be more difficult, the code remains the same. If the re-reduction is considerably more complex, and this is well documented in the operative report, append modifier 22: 19318-22. This will most probably require a letter of explanation to the payer.
- Bilateral breast reduction is reported with code 19318-50. Some payers may require a two-line entry:

19318  
19318-50

- Others may require the right and left modifiers:

19318-RT  
19318-LT

- All breast reduction procedures, whether primary or re-reductions, must be preauthorized in writing by the payer prior to surgery.

**CODING PRINCIPLE:** The breast reduction code is global and includes the following:

- Dissection and preservation of the nipple-areola complex on pedicle or harvest of nipple-areola complex as a free graft
- Parenchyma reduction, including liposuction
- Elevation, rotation, and transposition of breast flaps
- Nipple-areola transposition or application of nipple-areola free graft
- Wound closure, including excision of dog-ears
- Ninety days of routine postoperative care

**Disclosure:** Dr. Janevicius is the president of JCC, a firm specializing in coding consulting services for surgeons, government agencies, attorneys, and other entities.

scar. This can help raise the inframammary fold by removing the weight that pushed the fold down after the original breast reduction. The inframammary fold does not need to be sutured to the chest wall.

## CONCLUSIONS

Breast re-reduction can be performed safely if the surgeon follows the following principles: (1) maintain the nipple-areola complex on a random pattern blood supply by deepithelializing only, and not creating a new pedicle or even recreating the original pedicle; (2) correct the excess glandular ptosis by removing a vertically oriented inferior wedge of breast tissue even if it contains the original pedicle; (3) elevate the inframammary fold by removing the weight that pushes it down (this is best achieved by liposuction and direct excision between the bottomed-out inframammary fold and the original horizontal scar); (4) do not remove skin horizontally because the skin between the horizontal scar and the bottomed-out inframammary fold needs to be reverted to chest wall skin. If there is redundant skin on the breast, it should be removed above the inframammary fold scar.

*Elizabeth J. Hall-Findlay, M.D.*

Banff Plastic Surgery  
P.O. Box 2009  
317 Banff Avenue, Suite 340  
Banff, Alberta T1L 1B7, Canada  
ehallfindlay@banffplasticsurgery.ca

## REFERENCES

- Ahmad J, McIsaac SM, Lista F. Does knowledge of the initial technique affect outcomes after repeated breast reduction? *Plast Reconstr Surg.* 2012;129:11–18.
- Austin RE, Lista F, Ahmad J. Management of recurrent or persistent macromastia. *Clin Plast Surg.* 2016;43:383–393.
- Rohrich RJ, Thornton JF, Sorokin ES. Recurrent mammary hyperplasia: Current concepts. *Plast Reconstr Surg.* 2003;111:387–393; quiz 394.
- Rohrich RJ, Gosman AA, Brown SA, Tonadapu P, Foster B. Current preferences for breast reduction techniques: A survey of board-certified plastic surgeons 2002. *Plast Reconstr Surg.* 2004;114:1724–1733; discussion 1734.
- Frederick MJ, Lin AM, Neuman R, Smith BL, Austen WG Jr, Colwell AS. Nipple-sparing mastectomy in patients with previous breast surgery: Comparative analysis of 775 immediate breast reconstructions. *Plast Reconstr Surg.* 2015;135:954e–962e.
- Lejour M. Vertical mammoplasty as secondary surgery after other techniques. *Aesthetic Plast Surg.* 1997;21:403–407.
- Hudson DA, Skoll PJ. Repeat reduction mammoplasty. *Plast Reconstr Surg.* 1999;104:401–408.
- Losee JE, Caldwell EH, Serletti JM. Secondary reduction mammoplasty: Is using a different pedicle safe? *Plast Reconstr Surg.* 2000;106:1004–1008; discussion 1009.
- Spear SL. Discussion: Secondary reduction mammoplasty: Is using a different pedicle safe? *Plast Reconstr Surg.* 2000;106:1009–1010.
- Skoll PJ, Hudson DA. The safety of a different pedicle in secondary reduction mammoplasty. *Plast Reconstr Surg.* 2001;108:1086.
- Patel SP, Brown DL, Cederna PS. Repeated bilateral reduction mammoplasty: A 12-year experience. *Plast Reconstr Surg.* 2010;126:263e–264e.
- Hall-Findlay EJ. *Aesthetic Breast Surgery: Concepts & Techniques.* St. Louis: Quality Medical; 2011.
- Spear SL, Rottman SJ, Seiboth LA, Hannan CM. Breast reconstruction using a staged nipple-sparing mastectomy following mastopexy or reduction. *Plast Reconstr Surg.* 2012;129:572–581.
- Alperovich M, Tanna N, Samra F, et al. Nipple-sparing mastectomy in patients with a history of reduction mammoplasty or mastopexy: How safe is it? *Plast Reconstr Surg.* 2013;131:962–967.
- van Deventer PV, Graewe FR. The blood supply of the breast revisited. *Plast Reconstr Surg.* 2016;137:1388–1397.
- Hall-Findlay EJ. Discussion: The blood supply of the breast revisited. *Plast Reconstr Surg.* 2016;137:1398–1400.